Classification-based surgical management of cervical dumbbell tumor: a five-year retrospective review of 16 cases at Prince of Wales Hospital

YING Luk Hin[1], CHOW Tom Shiu Fung[1], CHAN David Yuen Chung[1]
[1]Division of Neurosurgery, Department of Surgery, Prince of Wales Hospital, Hong Kong

Introduction

Dumbbell tumor is an hourglass-shaped spinal tumor in which its growth is limited by the dura, intervertebral foramen or other nearby skeletal structures. There are up to 44% of dumbbell tumors arising at the cervical spine. Among different pathologies of dumbbell tumors, schwannoma and meningioma are the most common entities.

Successful spinal tumor resection relies heavily on a proper tumor classification for preoperative planning. Eden classification represents the first and the gold standard to classify these lesions. With the advancement of CT and MRI, other classification systems have been established. Toyama et al. devised an imaging-based classification system that consisted of nine categories based on the number of intervertebral and transverse foramina involved for cervical dumbbell tumor, which is more suitable for surgical planning.

Posterior laminectomy remains the first choice of surgical resection of symptomatic intraspinal tumors. But a laminectomy-only approach may render spinal instability or progression of spinal deformity as the spinal column may be weakened structurally during tumor removal, particularly when the tumor invades at multiple levels e.g. neurofibromas, extradural intravertebral tumors, multidirectionally eroding tumors. In this case, spinal reconstruction surgery using instrumentation should be considered. However, there is no consensus on a classification system that guides the optimal surgical approach for tumor resection.

Objective

We reviewed our operative case series of cervical dumbbell tumors and analysed the clinical outcome based on Toyama Classification to try developing an algorithm for devising the optimal surgical approach to achieve GTR with less procedure related risk for complications.

Method

We retrospectively collected and analyzed medical records of 16 patients who received resection of cervical dumbbell tumors (8 schwannomas and 8 meningiomas) between August 2017 to August 2022. Cases were reviewed through clinical history and physical examination from consultation notes and radiological images. Demographics were matched in terms of procedure performed (anterior / posterior approach, with or without instrumented reconstruction e.g. lateral mass screw, pedicle screw). Clinical outcomes of the two groups were compared in terms of the extent of resection (Gross Total Resection or SubTotal Resection), intra-operative complications, and neurological complications.

Results

Fig.2 Surgical approach of 16 cervical dumbbell tumors

Toyama class	Tumor size (cm)	Posterior approach only (laminectomy / facetectomy)	Extended bone resection with PSF
I	≤ 4	11	1
	> 4	0	1
IIA	≤ 4	0	1
	> 4	0	0
IIB	≤ 4	0	1
	> 4	0	0

Fig. 2 Among the 16 cases, there are 13 Toyama class I tumors, 2 class IIA tumors, and 1 class IIB tumor. Most of the Toyama class I tumor can be resected by posterior approach. 2 cases received extended bone resection with spinal reconstruction (one was complicated with C3-6 spinal stenosis, another involved multiple spinal levels having a size of 16cm in its largest dimension). All class IIA and IIB tumors had undergone extensive bone resection with spinal reconstruction.

All 16 cases achieved gross total resection. None of the cases experienced any intraoperative complications. Intra-operative blood loss of the two groups are comparable (simple: 150ml, PSF: 224ml).

Discussion

- Dumbbell tumors are associated with higher risk of complications e.g. CSF leakage, wound infection, pseudo-meningocele, spinal cord edema, cervical cord and nerve root compression, invasion to VA, carotid sheath, etc.
- **Gross total resection (GTR)** should be performed if there is no risk of vascular or neurological injury to minimise the risk of recurrence.
- **Subtotal resection (STR)** is done when the risk of neurovascular injury is high as suggested by intra-operative nerve monitoring.

- Toyama Classification provides the anatomical details to guide the surgical approach for the complete resection of cervical dumbbell tumor.
- **Toyama Class IIa and IIb** are more completely resected with extended bony removal supported by instrumented reconstruction.
- **Toyama Class I** cases can be sufficiently addressed by a posterior approach with good results.

- **Drawbacks of the study:**
  - limited sampling size, not all Toyama classes are involved
  - limited by the accuracy of tumour classification
  - limitation of Toyama classification: only for cervical level tumor

Toyama classification

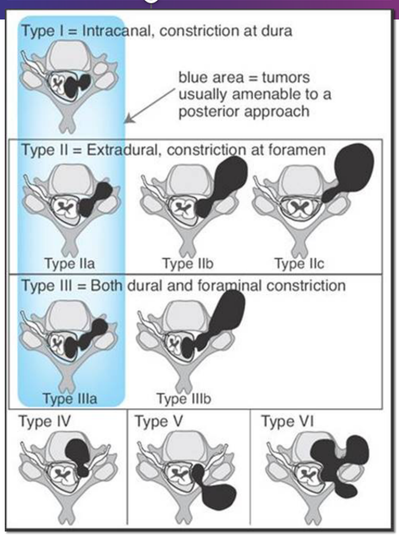

Fig.1 Classification of dumbbell spinal tumors
Asazuma T, Yoshiaki T, Hirofumi M, et al.: Surgical strategy for cervical dumbbell tumors based on a three-dimensional classification. Spine 29 (1): E10-4, 2003

Type I tumors are intradural and extradural and are restricted to the spinal canal; constriction at the dura
Type II are all extradural, and are subclassified as:
- **IIa** do not extend beyond the neural foramen,
- **IIb:** inside spinal canal + paravertebral,
- **IIc:** foraminal + paravertebral.

Type III is subclassified into:
- **IIIa:** intradural and extradural foraminal,
- **IIIb:** intradural and extradural paravertebral.

Type IV: extradural and intravertebral.
Type V: extradural and extralaminar with laminar invasion

Case 1

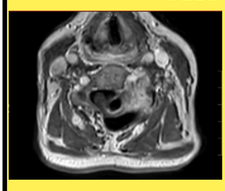

Fig. 3 (left) 76/F with history of C5/6 schwannoma and laminectomy done 23 years ago, had an increased left limb numbness & weakness. MRI showed a Toyama Class IIB tumor of size 39 x 25mm x 32mm compressing left VA V2 segment anteriorly with significant narrowing. Expanded left transverse foramen and eroded left pedicle with sclerotic margin at C5-6 levels were noted. Left C5/6 facetectomy & tumor excision with PSF was performed. GTR achieved. Intra-op blood loss 120ml, no immediate post-op complication
(right) Illustration of Toyama Class IIB tumor.

Case 2

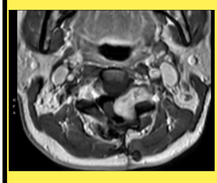

Fig. 4 48/F with history of C2-3 left schwannoma, operated 3 years ago, experienced worsening left limb numbness & weakness, neck and back pain. MRI revealed a Toyama Class IIA schwannoma at C2/3 level, sized 22 x 8mm, with enlargement of neural foramen. C2/3 facetectomy with tumor excision and reconstruction with PSF were performed. GTR achieved. Upper limb power showed improvement from 5/4 to 5/5. Intra-op blood loss 100ml, no immediate post-op complication. ***(Right)*** is an illustration of Toyama Class IIA tumor.

Conclusion

- Toyama classification can be used to guide the optimal surgical resection of cervical dumbbell tumors.
- A larger population size is needed to study tumors of other Toyama Classes.
- To further investigate, we propose a prospective study with a larger sampling size. The primary endpoint of the case study is re-operation, whereas the secondary end point is an alternative treatment (e.g. radiotherapy, chemotherapy) or development of neurological deficit

Reference
1. Asazuma, T., Toyama, Y., Watanabe, M. et al. Clinical features associated with recurrence of tumours of the spinal cord and cauda equina. Spinal Cord 41, 85–89 (2003)
2. Ozawa H, Kokubun S, Aizawa T, Hoshikawa T, Kawahara C: Spinal dumbbell tumors: an analysis of a series of 118 cases. J Neurosurg Spine. 2007;7(6):587–93.
3. Pojskić, M., Arnautović, K.I. (2019). Dumbbell Tumors of the Spine. In: Arnautović, K.I., Gokaslan, Z.L. (eds) Spinal Cord Tumors. Springer, Cham.