

A Case Study: Same Day Spontaneous Reduction of a Traumatic Infantile Depressed Skull Fracture

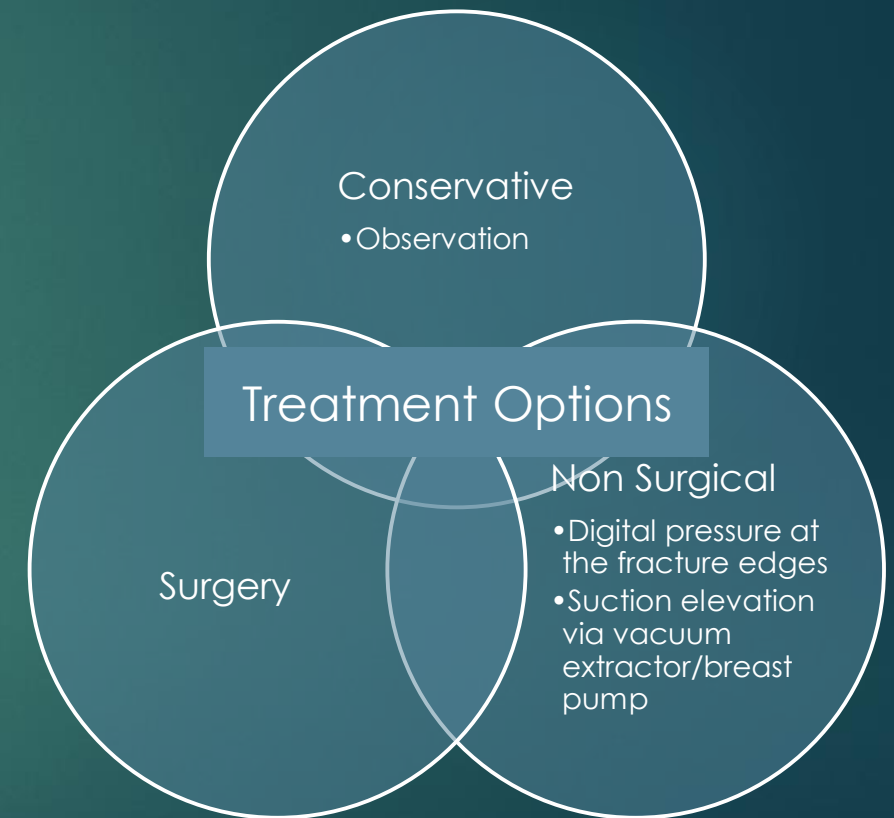
TANG KINGLAM, PO YIN CHUNG

DEPARTMENT OF NEUROSURGERY, PRINCESS MARGARET HOSPITAL, HONG KONG.



Introduction

- ▶ Depressed skull fractures occurring in the neonate or infant are termed “Ping Pong” fractures and refer to a depression of the skull vault without a cortical break.
- ▶ Causes of neonatal depressed skull fractures: faulty foetal packing, birth trauma, maternal pelvic/vertebral anomalies.
- ▶ Postnatal depressed skull fractures are mainly due to head trauma and account for as much as 7-10% of all paediatric head injury admissions.
- ▶ Conservative management is advised in the absence of brain injury as the deformity will often correct itself as the skull grows over the following months.
- ▶ Herein, we present a rare case of an infantile traumatic depressed skull fracture that spontaneously resolved within 4 hours of the injury.
- ▶ To the best of our knowledge, this is just the third case of an infantile depressed skull fracture to have spontaneously resolved within the same day of injury.



Case Presentation

A 9-mth old male presented with a palpable skull depression after falling from sofa height.



An AED skull X-Ray showed a 6.43mm deep right parietal skull fracture (Figure A).



A CT scan was ordered to rule out underlying brain injury.



Clinically, the patient was irritable but was otherwise well.



However, the fracture spontaneously reduced during a crying episode while waiting for the CT scan; just under **4 hours** post injury!



CT Brain confirmed complete fracture reduction with no neurological complications (Figure B).

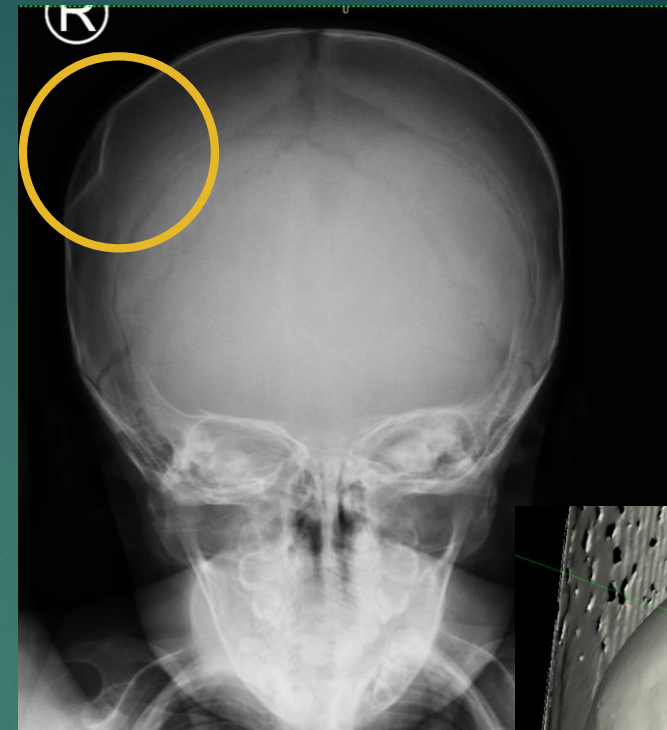
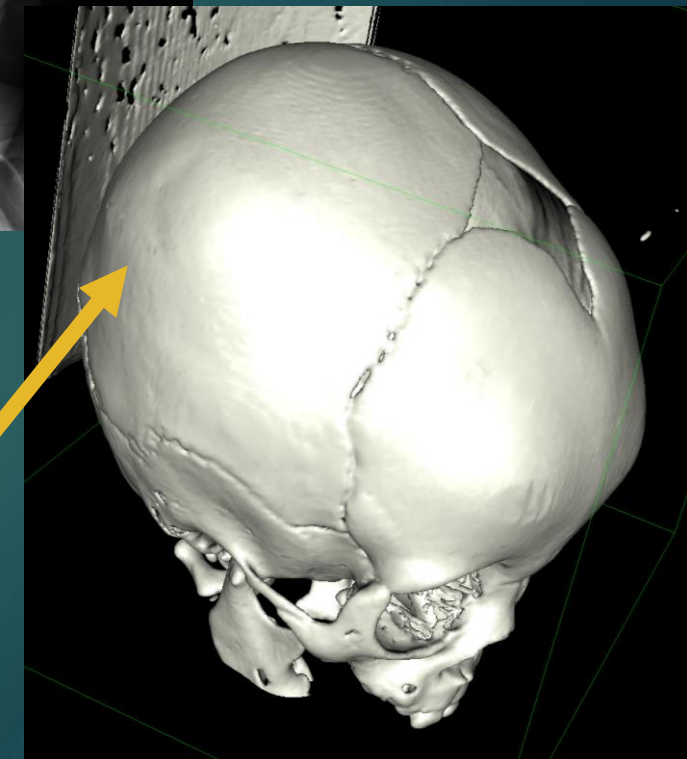


Figure A



Resolution of depressed skull fracture

Figure B

Management and Outcome

- ▶ In view of the reduction and lack of underlying brain injury, the patient was treated conservatively.
- ▶ His progress was followed up in the out-patient setting.
- ▶ Clinically, the child was well and there were no neurological or cosmetic sequelae.

Discussion and Conclusions

- ▶ Typically, surgical treatment is required if there were complications including underlying brain injury, intracranial bleeding, increased intracranial pressure or poor cosmetic recovery.
- ▶ There are no predictors to distinguish which fractures will elevate spontaneously. Literature advise for a 6-month observation period in the absence of neurological symptoms as most skull depressions resolve within 4 months.
- ▶ Steinbook et al. demonstrated no differences in neurological or cosmetic outcomes between surgical and non-surgical treatment in children with depressed skull fractures.

Discussion and Conclusions

- ▶ In our case, a nonsurgical fracture reduction was undertaken by the patient himself. It is postulated that the patient's crying episode had temporarily increased the intracranial pressure (ICP) high enough and for a period long enough to reduce the fracture.
- ▶ Crying is a known physiological cause for temporary rises in ICP as it increases intrathoracic pressure and blood pressure. However, no literature could be found that estimated the level of ICP that can be generated during a crying episode. Normally, ICP values in infants range from 1.5-6mmHg. An ICP \geq 20mmHg for longer than five minutes is regarded as abnormal.
- ▶ Other factors that assisted reduction is due to the increased plasticity of the paediatric skull vault contributed by incomplete skull ossification, relative thinness of the infantile calvaria and the membranous nature of the sutures.
- ▶ A literature search was performed over PubMed, Cochrane Central and EBSCOhost with the keywords: skull, depressed, ping-pong, fracture, paediatric, spontaneous, resolution.
- ▶ To the best of our knowledge, there are only two other reported cases of depressed skull fractures that spontaneously resolved within 24 hours of admission.
- ▶ Ross (1975) reported a case of a 3-month-old infant whose depressed skull fracture spontaneously resolved 4 hours after admission; whereas Sorar et al. (2013) reported a case involving a 11-month-old infant that reduced in 2 hours.

Discussion and Conclusions

- ▶ Like our case, both Ross and Sorar et al. attributed the fracture reduction to increased intracranial pressure due to crying. Additionally, Sorar et al.'s case also noted intractable vomiting in the patient which may have contributed to the raised intracranial pressure.
- ▶ None of the cases described incurred cosmetic or neurodevelopmental sequelae.
- ▶ Conclusion: Management decisions should be based on the presence of neurological complications detected on imaging and clinical examination. Watchful waiting can be undertaken in those without neurological complications. Cosmetic concerns should be considered but an observation period of around 6 months should be allowed since most depressions will resolve itself within 4 months.

REFERENCES:

- Williams, H. (2008). Lumps, bumps and funny shaped heads. *Arch Dis Child Educ Pract Ed*, 93, 120-128.
- Preston, D., Jackson, S., & Gandhi, S. (2015). Non-traumatic depressed skull fracture in a neonate or 'ping pong' fracture. *BMJ Case Rep*.
- Sorar, M., Fesli, R., Gurer, B., Kertmen, H., & Sekerci, Z. (2012). Spontaneous Elevation of a Ping-Pong Fracture: Case Report and Review of the Literature. *Paediatric Neurosurgery*, 48, 324-326.
- Tayeh, C., Bali, B., Milad, N., & Najjar, M. (2016). Congenital depression of the skull in a neonate. *BMJ Case Rep*.
- Cohen, A. R., Bahuleyan, B., & Robinson, S. (2011). Unusual Resolution of a Depressed Skull Fracture following Repeat Head Trauma: The Two-Hit Hypothesis? *Paediatric Neurosurgery*, 47, 230-232.
- Steinbok, P., Flodmark, O., Martens, D., & Germann, E. T. (1987). Management of simple depressed skull fractures in children. *J Neurosurg*, 66, 506-510.
- Ross, G. (1975). Spontaneous elevation of a depressed skull fracture in an infant. Case Report. *J Neurosurg*, 42, 726-727.
- Canac, N., Jaleddini, K., Thorpe, S. G., Thibeault, C. M., & Hamilton, R. B. (2020). Review: pathophysiology of intracranial hypertension and noninvasive intracranial pressure monitoring. *Fluids and Barriers of the CNS*, 17.