



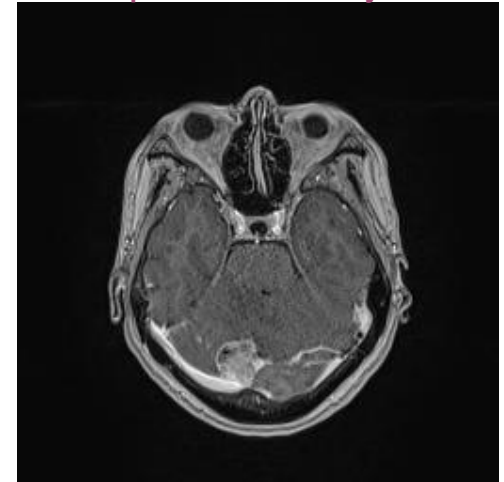
A Case Report of Intracranial Angiomatoid Fibrous Histiocytoma: The first case in Asia and of the oldest age so far

By CHAN Yin Man, TSE Po Ki Teresa, CHOW Kwan Ho, PO Yin Chung
From Department of Neurosurgery, Princess Margaret Hospital

Case Description

- A case report of intracranial AFH being treated and followed-up at the Department of Neurosurgery, PMH, since 2018
- **First case** of intracranial AFH in **Asia** and of the **oldest** patient with intracranial AFH ever reported
- F/67
- Self-ambulatory
- Past medical history:
 - Ischaemic heart disease, on aspirin
 - Hypothyroidism, on thyroxine replacement
- Presentation:
 - **Worsening vertigo** in mid-2018
 - P/E: right intention tremor with no other neurological deficit
- Investigations:
 - MRI brain:
 - A **right posterior cranial fossa extra-axial torcular lesion**
 - Vasogenic edema
 - Mild hydrocephalus
 - Abutting the torcula herophili, right transverse sinus and occipital sinus
 - PET-CT: no evidence of any primary malignancy or distant metastasis
 - Tumour markers: unremarkable

Pre-operative MRI in July 2018

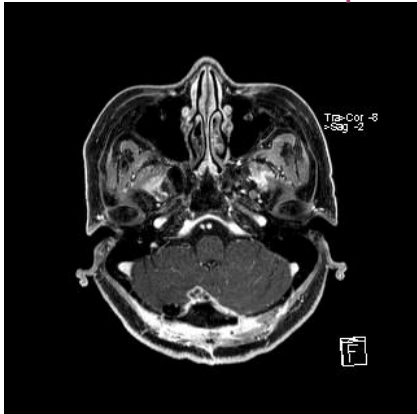

Pre-operative MRI brain in July 2018 showed a 2.9x2.8x3.1cm (TSxAPxCC) right posterior cranial fossa extra-axial mass with vasogenic edema.

Operations

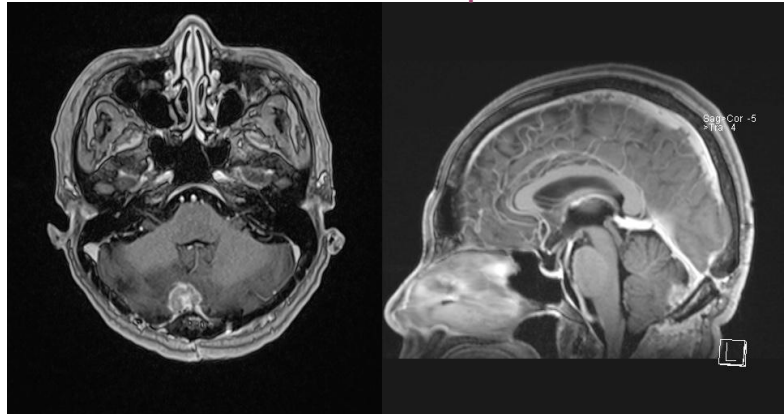
- First tumour excision in August 2018
 - **Small residual tumour** left behind due to **close adherence to torcular sinus**
- Recurrence **7 months** after first excision
 - Presented with worsening vertigo again
 - MRI brain: interval enlargement of residual tumour
- Second tumour excision in July 2019
 - **Clear resection margin** achieved with **opening of torcular sinus**
- **No recurrence** on subsequent follow-up MRI scans

Residual tumour after first operation



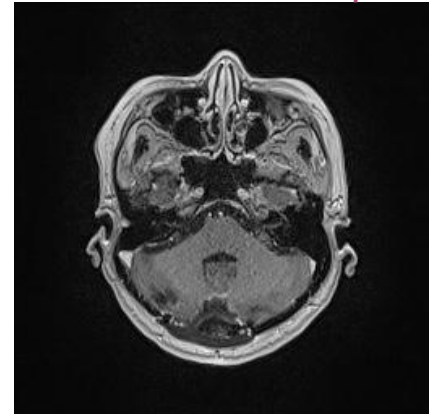
MRI brain in October 2018 showed a 10x6x7mm (transaxial x height) residual nodular lesion with rim enhancement at the resection margin.

Recurrence after first operation



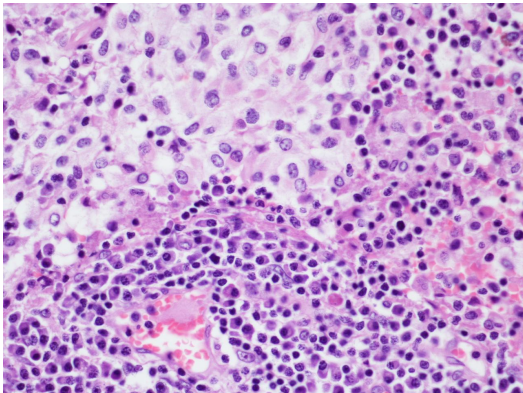
MRI brain in March 2019 showed interval enlargement of the residual tumour (1.6x1x1.9cm) with perifocal edema. It abutted the straight sinus as shown.

No recurrence after second operation

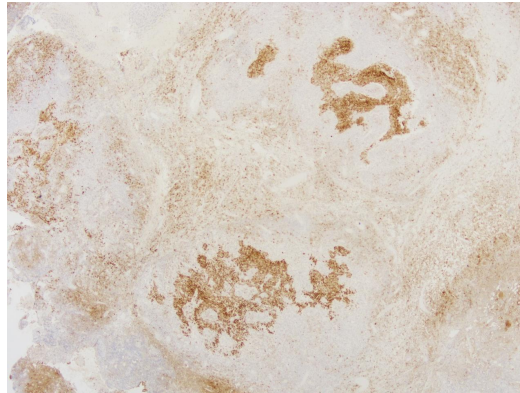


MRI brain in August 2019 showed no evidence of tumour recurrence.

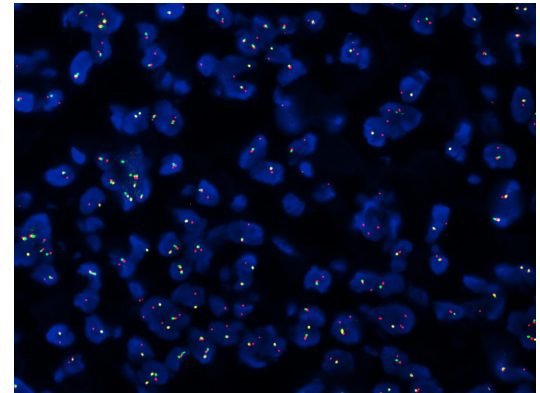
- Pathological features of the resected specimen:
 - **Dense plasmacytosis**
 - **Focal increase in IgG4-positive plasma cells**
- Uncertain significance of the pathological features
 - Fall short of diagnostic histological criteria of IgG4-related disease
 - May correlate with serum IgG4 level
- Diagnosis of intracranial AFH confirmed with AFH-consistent genetic markers
 - Fluorescence in-situ hybridization (FISH): **EWSR1 gene rearrangement** in >50% of tumour cells
 - Reverse transcription and real-time PCR: **negative** for EWSR1-ATF1 and EWSR1-CREB1 fusion transcripts
 - Illumina Pan-cancer RNA-sequencing panel analysis: **positive** for chimeric transcript **EWSR1-CREM** and chimeric transcript **CRKL-PI4KA**



Dense plasmacytosis



CD68 staining for IgG4-positive plasma cells



FISH showed EWSR1 gene rearrangement.



Discussion



- Angiomatoid fibrous histiocytoma (AFH)
 - Rare **low-grade soft tissue** neoplasm
 - More commonly affects the **extremities**
 - More commonly occurs in **children** and **young adults**
 - **Infrequently recurs** and **rarely metastasizes**
 - Only **5 case reports** of **intracranial** AFH published worldwide so far
- The ages of the previously published cases ranged from **17 to 58**. The age of our patient is 67, which is the oldest so far.
- All of the previously published cases were reported in the **United States** or the **United Kingdom**. Our patient is the first reported case in Asia with intracranial AFH.
- EWSR1 gene rearrangement with or without EWSR1 fusion gene have been described in **4** of the previously published 5 case reports.
- Gross total excision was the treatment for **4** of the previous cases, **3** out of which had no recurrence after gross total excision.

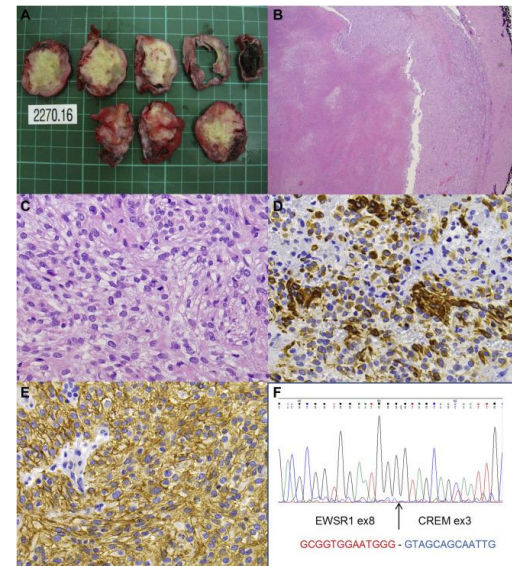
Author, Year	Age/Sex	Presentation	Tumour location	Genetic marker(s)	Treatment	Outcome
Dunham et al., 2008	25/Male	Headache, vomiting and visual disturbance	Left occipital lobe	EWSR-ATF1 fusion gene	Gross total excision	No recurrence
Ochalski et al., 2010	35/Male	Right facial weakness	Left temporal lobe	Rearranged EWSR1	8 times of gross total excision , and GKR	8 recurrences, and death from hydrocephalus
Hansen et al., 2015	17/Female	Headache, visual disturbance and anaemia	Bilateral occipital lobes	None	Gross total excision	No recurrence
Alshareef et al., 2016	58/Female	Right facial weakness and pain	Right porous trigeminus	Rearranged EWSR1	Gross total excision	No recurrence
Sion et al., 2020	43/Male	Headache, visual disturbance and transient dysphasia	Left occipital lobe and left suboccipital lobe	EWSR1-ATF1 fusion gene	Excision with significant debulking (95%)	Surveillance with MRI in 6 months



Conclusion



- **Intracranial** involvement of AFH is **exceedingly rare**.
 - Only a few case reports are available worldwide.
 - Our case is the **first** case in **Asia** and is of the **oldest** age so far.
- **EWSR1 gene rearrangement** with or without EWSR1-ATF1 fusion gene is a typical feature to support the diagnosis of AFH.
- The behaviour of AFH could be **locally invasive** with **rapid growth**.
- **Gross total resection** is the treatment of choice for AFH.



Source: ScienceDirect.com