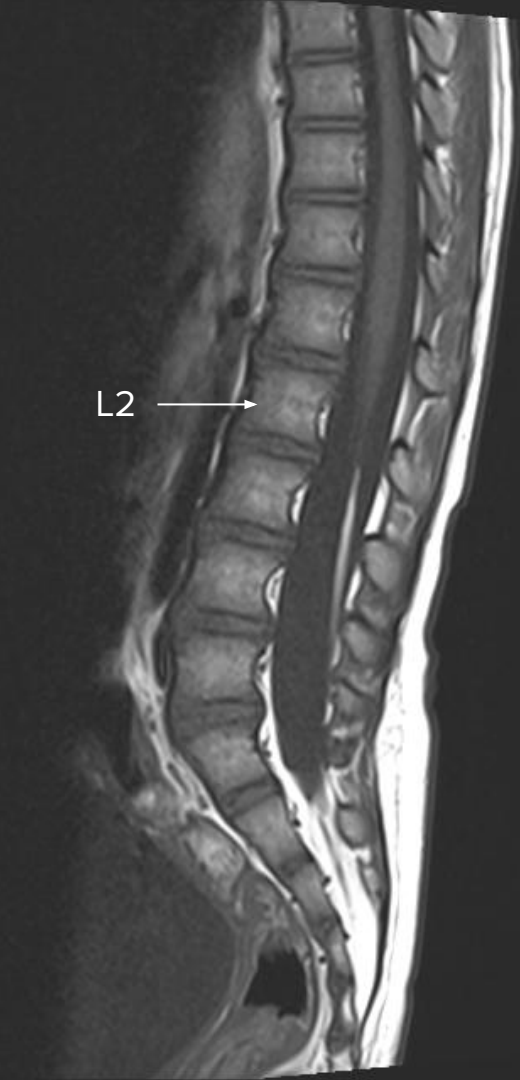

Case report of 2 children with sectioning of
filum in **occult cord tethering** presenting
with neurogenic bladder

Tsui WYR, Chow SWJ, Cheung FC

Department of Neurosurgery, Queen Elizabeth Hospital,
Hong Kong.



Occult Tethered Cord Syndrome (OTCS)

Symptom of tethered cord with normal conus position, predominantly with urological symptom ¹

Current recommendation by The International Children's Continence Society - Insufficient evidence to support routine use of untethering in OTCS ²

Picture to the left showed a T1-weighted MRI of a 5-years-old with OTCS

- conus at normal level L2-3
- long segment of fatty filum from upper L3 to S1/2

1. Fabiano AJ, Khan MF, Rozzelle CJ, Li V (2009) Preoperative predictors for improvement after surgical untethering in occult tight filum terminale syndrome. *Pediatr Neurosurg* 45:256–261
2. Tuite GF, Thompson DNP, Austin PF, Bauer SB. Evaluation and management of tethered cord syndrome in occult spinal dysraphism: Recommendations from the international children's continence society. *Neurourol Urodyn*. 2018 Mar;37(3):890-903. doi: 10.1002/nau.23382. Epub 2017 Aug 9. PMID: 28792087.



Objective

- A recent pilot RCT
 - compared outcome between surgical and non surgical treatment to paediatric patients with **OTCS**,
 - no statistically significant difference ³

- We hereby present 2 cases from our centre who received cord untethering, demonstrating the efficacy and safety of the surgical option.

3. Steinbok P, MacNeily AE, Hengel AR, et al. Filum Section for Urinary Incontinence in Children with Occult Tethered Cord Syndrome: A Randomized, Controlled Pilot Study. The Journal of Urology. 2016 Apr;195(4 Pt 2):1183-1188. DOI: 10.1016/j.juro.2015.09.082.

Case summary:

	Case 1	Case 2
Age receiving operation / Sex	5 / Female	9 / F
Presentation	<ul style="list-style-type: none">• nocturnal enuresis (NE)• Urodynamic studies: neurolarge bladder capacity• tip-toeing gait	<ul style="list-style-type: none">• polyuria, daytime urinary urge incontinence• nocturnal enuresis• never achieved continence
Physical exam finding	<ul style="list-style-type: none">• tight Achilles tendon with increased lower limb tone, increased lower limb reflex	<ul style="list-style-type: none">• bilateral lower limb tone normal, mildly increased bilateral knee reflex
MRI conus medullaris level	L2	L2
Outcome	<ul style="list-style-type: none">• no more NE• Achilles tendon less tight, gait normal	<ul style="list-style-type: none">• decrease urinary frequency• no more incontinence

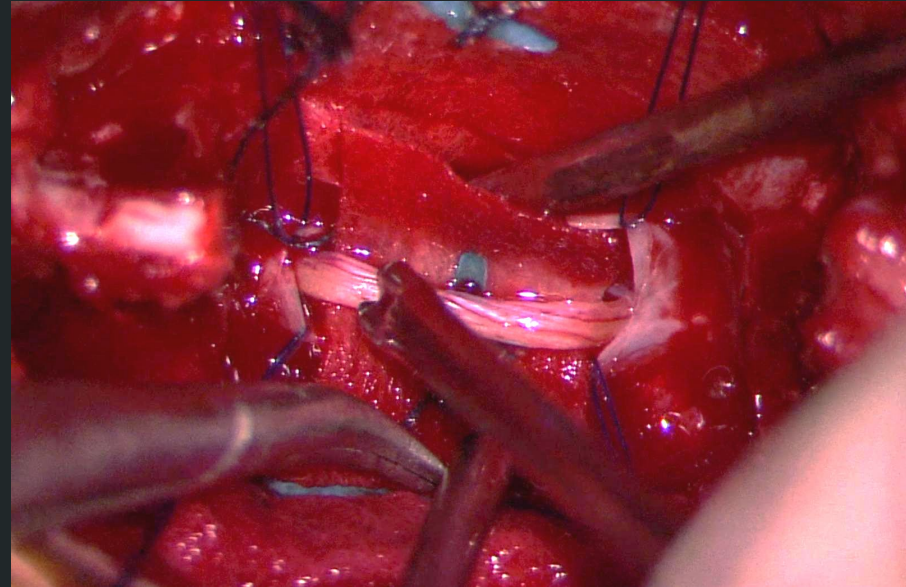
Outcome

Case 1

- no more NE
- improved LL tone, no more tip-toeing gait

Case 2

- decrease urinary frequency
- no more incontinence



Intra-op photo of the fatty filum with
stimulation probe applied



Conclusion

- outcome: improvement in symptom, no known complication; consistent with literature review of 12 retrospective studies where 78.3% of paediatric patients showed improvement in symptoms ⁴
- no conclusive data for optimal age and timing for surgery
- but our case report demonstrated that early surgery is safe and prevent symptomatic patients with OTCS from irreversible physical and neurological damage

4. Tu A, Steinbok P. Occult tethered cord syndrome: a review. Child's Nervous System : Chns : Official Journal of the International Society for Pediatric Neurosurgery. 2013 Sep;29(9):1635-1640.