“Spooky Action at a Distance”
A Report of Two Cases of Distant Wounded Glioma Syndrome.

By Poon, W.C.; Ho, L.Y.; Pang K.Y.
Department of Neurosurgery, Pamela Youde Nethersole Eastern Hospital, Hong Kong.

Cases of distant wounded glioma syndrome in our centre

We present two cases of distant wounded glioma syndrome. Two gentlemen in their 60s with multiple brain lesions on presentation. Both patients had undergone craniotomy and tumor excision on the left frontal lesions. In the CT Brain done on post-operative day one, both cases showed haemorrhage at a lesion of a distant site not manipulated during the operation: one over the right frontal region and the other at the left temporal region.

Case 1

65 /M
- History of hypertension and ischemic heart disease
- Not on antiplatelet therapy due to defaulted appointment
- Presented with generalized tonic clonic seizure
- MRI revealed a left frontal contrast enhancing lesion and also lesions of similar appearance over the right frontal region.
-Craniotomy and tumour excision was performed. Only the left frontal tumor was resected while the right frontal lesions were left untouched.
- CT on post-operative day 1 showed haemorrhage over the right frontal lesions.

Case 2

62/M
- History of diabetes
- Presented with confused speech and expressive dysphasia
- CT and MRI showed multiple rim enhancing lesions over left frontal and temporal lobes
- Gross total excision was performed on left frontal tumour while the left temporal tumours were left untouched.
- CT Brain done after the operation showed left temporal tumour bleeding.

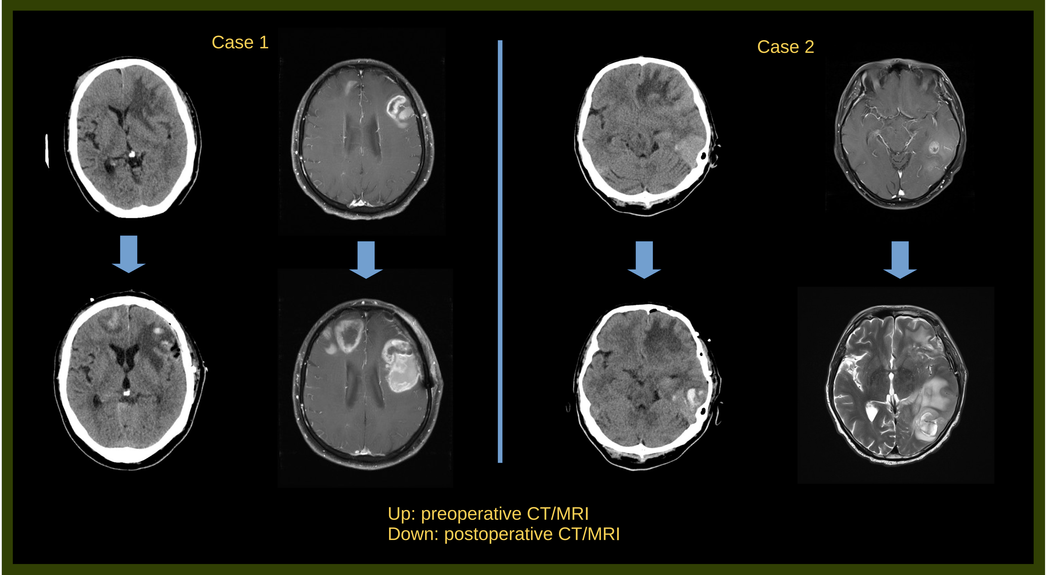

Up: preoperative CT/MRI
Down: postoperative CT/MRI

Outcome

Pathological examination of the resected specimens in both cases revealed glioblastomas. Both cases were managed conservatively with no immediate deficits. Both patients had no coagulopathy with no hypertension during the perioperative period as we reviewed the anesthetic records after the operation.

Literature review

We reviewed the English Literature and found two previously reported cases with the same phenomenon of post-operative haemorrhage in a distant tumor not manipulated during glioma surgery. The author named this phenomenon “**Distant wounded glioma syndrome**” as inspired by the more commonly known “wounded glioma syndrome”, where haemorrhage occurred in the partially resected glioma. Below is the summary of the two previously reported cases.

Patient A

- 49/M, Caucasian
- presented with a 6-week history of speech difficulties, dense right homonymous hemianopia and moderate expressive aphasia.
- MRI: cystic mass in the middle and posterior left temporal lobe, with a distant nodule in the left periventricular area.

- Underwent an image-guided resection of the left temporal tumor mass.
- The patient awakened with new right hemiparesis and baseline aphasia.
- Postoperative CT revealed new hemorrhage at the remote tumor site in the left periventricular region extending into the left corona radiata, confirmed by MRI performed the following day.
- This patient recovered with slight right upper-extremity weakness.

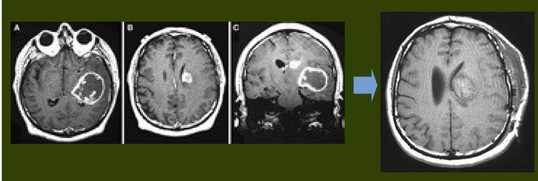

Preoperative (left) and postoperative (right) MRI scan of Patient A

Patient B

- 50/M, Caucasian
- Previously undergone surgical resection of a right frontal glioblastoma multiforme
- Presented with the recurrence of headaches.
- No neurological deficits.
- MRI showed a large right frontal lesion with edema and a midline shift and a distant tumor in the right subcortical primary motor cortex.

- Underwent a craniotomy and a right frontal lobectomy
- Gross total resection of the primary lesion
- Intraoperative MRI revealed no residual tumor in the right frontal lobe
- Distant tumor in the primary motor cortex remained untouched.
- Experienced generalized tonic-clonic seizure and postictal left hemiparesis immediately after surgery.
- CT performed after surgery revealed hemorrhage at the distant tumor near the right subcortical primary motor cortex area. This patient developed sepsis and died due to multisystem organ failure.

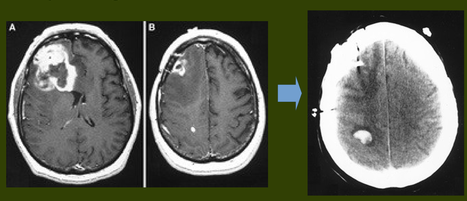

Preoperative (left) and postoperative (right) MRI/CT scan of Patient B

Discussion

In view of the reported cases, distant wounded glioma syndrome could be a lesser known but distinct complication from glioma surgery. It was proposed that systemic hypocoagulable state induced by tumor resection and hemorrhage-prone vessels of the distant gliomas cause distant wounded glioma syndrome. Previous thromboelastographic study of 50 patients which included a group of patient who developed haematoma after glioma surgery revealed a significant decrease in platelet counts and an increase in partial thromboplastin times in the post operative blood tests in that group, suggesting that surgical resection of the tumor created an immediate systemic coagulation dysfunction. It was also reported that there is local release of tissue plasminogen activator into the systemic circulation, as measured in blood samples taken from the jugular bulb during surgery to treat a glioblastoma multiforme that hemorrhaged at the time of presentation.

Conclusion

Distant wounded glioma syndrome is a distinct complication of glioma excision surgery. Surgeons should acknowledge this complication when determining surgical plan for resection of glioblastoma multiforme. Haemorrhage over the distant tumor after excision of the major tumor may also suggest an alternative non-locally acting mechanism for the more common wounded glioma syndrome. Preliminary research suggested that a systemic hypocoagulable state induced by tumor resection may be the culprit. Further research may be done to verify this mechanism.

References:

1. Koebbe CJ, Sherman JD, Warnick RE. Distant wounded glioma syndrome: report of two cases. Neurosurgery. 2001;48(4):940-944. doi:10.1097/00006123-200104000-00053
2. Kreth FW, Thon N, Simon M, et al. Gross total but not incomplete resection of glioblastoma prolongs survival in the era of radiochemotherapy. Ann Oncol. 2013;24(12):3117-3123. doi:10.1093/annonc/mdt388
3. Brisman MH, Bederson JB, Sen CN, Germano IM, Moore F, Post KD: Intracerebral hemorrhage occurring remote from the craniotomy site. Neurosurgery 39: 1114–1122, 1998.
4. Ciric I, Ammirati M, Vick N, Mikhael M: Supratentorial gliomas: Surgical considerations and immediate postoperative results. Neurosurgery 21: 21–26, 1987.
5. Fukamachi A, Koizumi H, Nukui H: Postoperative intracerebral hemorrhages: A survey of CT findings after 1074 intracranial operations. Surg Neurol 23: 575–580, 1985.