



香港中文大學
The Chinese University of Hong Kong



香港中文大學醫學院
Faculty of Medicine
The Chinese University of Hong Kong

A rare case of spinal epidural abscess in a healthy teenage girl without risk factor: case report and literature review

Dr LEE Yee Ting ^{1,2}, Dr YEUNG Kam Tong ¹, Dr MAK Wai Kit ¹,
Dr CHAN Kit Ying ¹, Dr ZHU Xian Lun ¹, Dr CHAN Tat Ming ¹

¹ Division of neurosurgery, Department of Neurosurgery, Prince of Wales Hospital Hong Kong

² Department of Imaging and Interventional Radiology, Prince of Wales Hospital Hong Kong

Abstract

- We report a case of thoracic spinal epidural abscess in a 15 years old girl who was immunocompetent. Our case is unusual in that a spinal epidural abscess developed in a 15-year-old girl, who was immunocompetent, and lacked any predisposing factors. The main objective of this case report is to raise the awareness for rare spinal epidural abscess in immunocompetent young patient.



Background

- Spinal epidural abscess is an uncommon infection, with annual incidence of 5.1 cases per 10,000 admissions. It is a rare condition in children, with average age of presentation at 57.5 +/- 16.6 years ⁽¹⁾. Spinal epidural abscess is rare in individuals who are immunocompetent, rare still is the occurrence of spinal epidural abscess in patient lacking any comorbid condition, such as diabetes mellitus, intravenous drug abuse, chronic renal failure, which can be identified in 84% of spinal epidural abscess cases ⁽²⁾.



Case report

- A 15-year-old girl with good past health and normal development presented to Emergency Unit for 2-day history of severe back pain. On the 2nd Emergency Unit attendance, she developed paraplegia and urinary retention. She was admitted and urgent MRI revealed a T8-10 spinal epidural mass with cord compression. (Figure 1)
- Emergency laminectomy for cord decompression was performed. The intra operative specimen growing Methicillin Sensitive Staphylococcus Aureus (MSSA). Post operative MRI was taken, showing no residual lesion and spinal cord was well decompressed. (Figure 2)

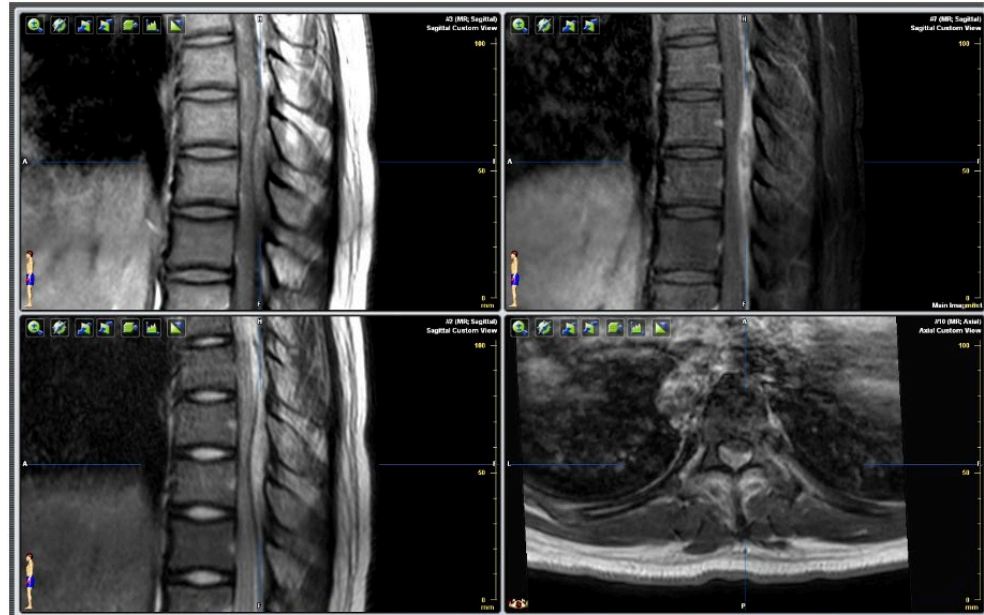


Figure 1 . MRI spine taken on day 1 presentation, showing T8-10 extradural lesion with peripheral enhancement and central hypoenhancing area, exhibiting T1 intermediate and T2 hyperintense signal.

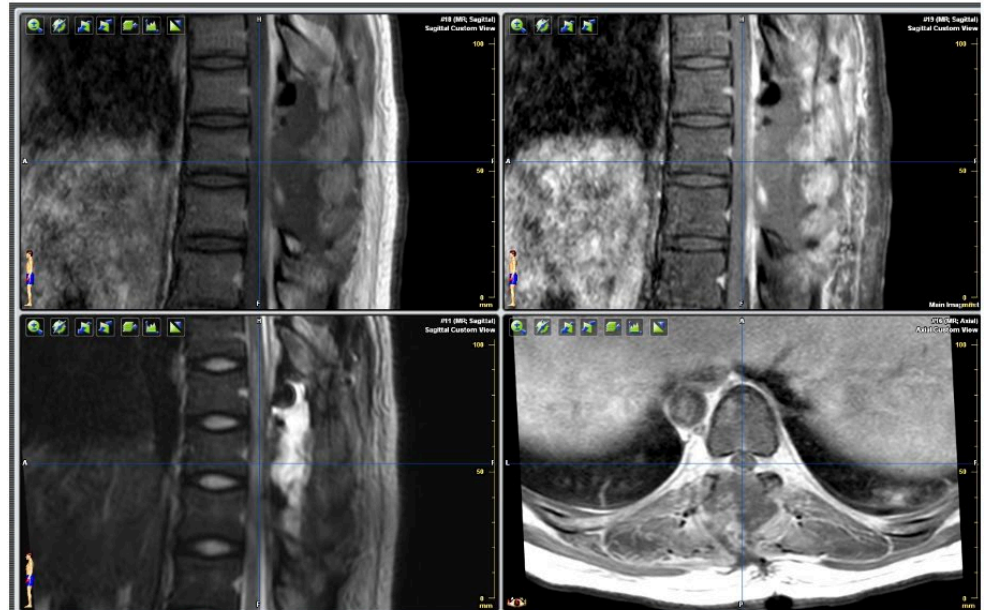


Figure 2 . MRI spine on post operation day 2, showing no residual enhancement lesion

Results

- Workup for primary source was negative without dental abscess and valve vegetation. Precipitating factor for invasive MSSA infection was all negative such as IV drug use, HIV, hepatitis B/C and diabetes mellitus. However, screening CT thorax, abdomen & pelvis revealed features of bilateral sternoclavicular joint septic arthritis. (Figure 3)
- Clinically, patient was asymptomatic of the arthritis. She received more than 6-week course of antibiotics with interval MRI confirmed complete resolution of spinal epidural abscess. (Figure 4) Her lower limb power gradually improved. By two months after the operation, she was able to walk with elbow clutches with assistance, with residual right foot drop and clonus.

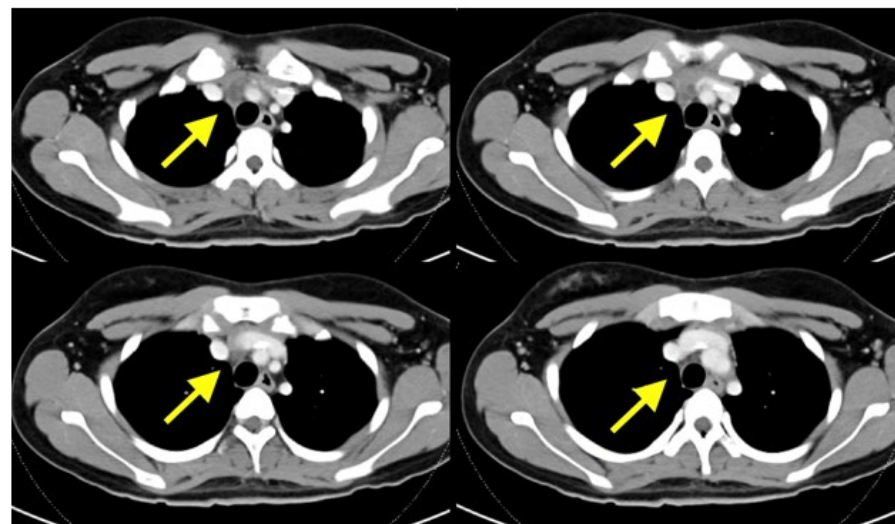


Figure 3. CT thorax showing 2 focal lesion in anterior mediastinum, with heterogeneous multicystic appearance, and closely related to bilateral sternoclavicular joint

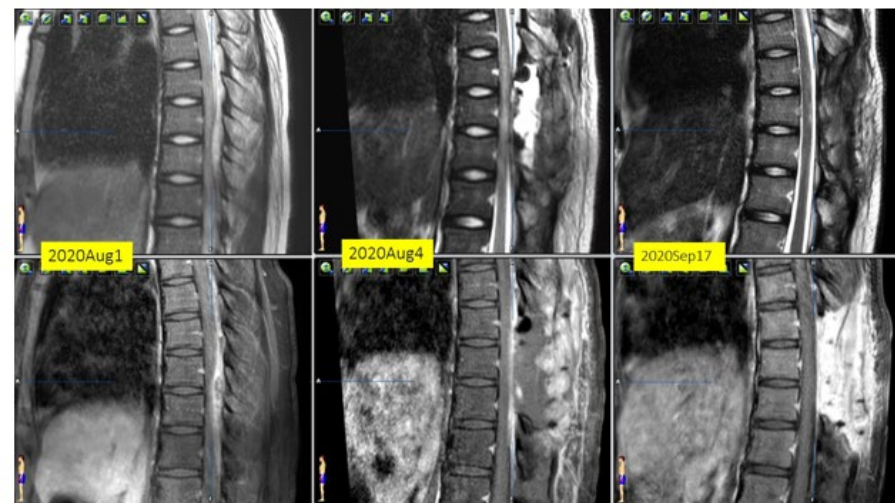


Figure 4. Interval MRI showing resolution of spinal epidural abscess and no recurrence after completion of course of antibiotics

Discussion

- Spinal epidural abscess in an immunocompetent paediatric patient without risk factors is an extremely rare condition. In a case report and literature review ⁽³⁾, there were only 31 reported cases. Early diagnosis, prompt surgical decompression and appropriate antibiotics is the key treatment for functional recovery. For the current case, the imaging diagnosis of bilateral sternoclavicular joint septic arthritis is suspected to be part of the infection foci.

Conclusion

- Although spinal epidural abscess in an immunocompetent paediatric patient without risk factors is rare, awareness of it with timely diagnosis is imperative to prevent devastating consequence of permanent neurological deficit or even death.

Reference

- (1) Greenberg MS. Handbook of Neurosurgery. 8th ed. New York, NY: Thieme; 2016.
- (2) The American Journal of Medicine (2017) 130, 1458–1463
- (3) Spinal Epidural Abscess in Children: Case Report and Review of the Literature. World Neurosurg. 2019 Jun;126:453-460.

